

1	APPARENT MODE ACCIDENT/ SUICIDE	CASE NO 2012-06359
	SPECIAL CIRCUMSTANCES Media Interest	CRYPT 62

LAST, FIRST MIDDLE: **LEWIS, JONATHAN KENDRICK** AKA: #

ADDRESS: **3605 LOWRY RD.** CITY: **LOS ANGELES** STATE: **CA** ZIP: **90027**

SEX	RACE APPEARS	DOB	AGE	HGT	WGT	EYES	HAIR	TEETH	FACIAL HAIR BEARD AND MUSTACHE	ID VIEW	CONDITION
MALE	CAUCASIAN	10/29/1983	28	67 in.	148 lbs.	BLUE	BROWN	ALL NATURAL TEETH		Yes	HEAD TRAUMA

MARK TYPE	MARK LOCATION	MARK DESCRIPTION
TATTOO	RIGHT SHOULDE	BLUE AND BLACK STAR
TATTOO	LEFT SHOULDER	RED AND BLUE STAR
TATTOO	UPPER BACK	SYMBOL

RELATIONSHIP: **FATHER** PHONE: NOTIFIED BY: DATE: **9/26/2012** TIME: **16:30**

SSN: DL ID: **D1316639** STATE: **CA** PENDING BY:

ID METHOD: **FINGERPRINTS FROM LASD**

LA #: MAIN #: **33251316** CH #: **A32513079** FBI #: **790986ND5** MILITARY #: POB:

IDENTIFIED BY: **AFIS@LACRIS, DOJ & FBI** RELATIONSHIP: PHONE: DATE: **9/26/2012** TIME: **18:42**

PLACE OF DEATH / PLACE FOUND: **DRIVEWAY** ADDRESS OR LOCATION: **3605 LOWRY RD.** CITY: **LOS ANGELES** ZIP: **90027**

PLACE OF INJURY: **DRIVEWAY** AT WORK: **No** DATE: **9/26/2012** TIME: **10:40** LOCATION OR ADDRESS: **3605 LOWRY RD., LOS ANGELES, CA** ZIP: **90027**

DOD: **9/26/2012** TIME: **10:57** FOUND OR PRONOUNCED BY: **LAFFD ENG 56**

OTHER AGENCY INV. OFFICER: **LAPD NORTHEAST - DETS. MARTIN & ZESATI** PHONE: **(323) 344-5744** REPORT NO.: NOTIFIED BY: NO:

TRANSPORTED BY: **JOHN KILLEN** TO: **LOS ANGELES FSC** DATE: **9/26/2012** TIME: **17:53**

FINGERPRINTS?	Yes	CLOTHING	No	PA RPT	No	MORTUARY	
MED. EV.	Yes	INVEST. PHOTO #	14	SEAL TYPE	NOT SEALED	HOSP RPT	No
PHYS. EV.	No	EVIDENCE LOG	Yes	PROPERTY?	Yes	HOSP CHART	No
SUICIDE NOTE	No	GSR NO		RCPT. NO.	261105	PF NO.	

SYNOPSIS
 ACCORDING TO THE AVAILABLE INFORMATION, THE DECEDENT IS A 28-YEAR-OLD WHITE MALE WHO WAS FOUND WITH HEAD TRAUMA LYING IN A DRIVEWAY AT THE ABOVE LOCATION. THE DECEDENT IS THE SUSPECT IN A HOMICIDE DEATH (CORONER CASE 2012-06358) AND MULTIPLE ASSAULTS THAT OCCURRED AT THE SAME LOCATION. HE APPEARS TO HAVE JUMPED FROM AN ELEVATED TERRACE TO THE DRIVEWAY WHILE ATTEMPTING TO FLEE THE SCENE. DURING THE APPROXIMATELY 15 FOOT DROP HE APPARENTLY LOST HIS BALANCE OR STRUCK AN OBJECT. THIS CAUSED HIM TO LAND SO HIS HEAD IMPACTED THE CONCRETE DRIVEWAY. THE DECEDENT WAS POSSIBLY UNDER THE INFLUENCE OF DRUGS DURING THE TERMINAL EPISODE. THE DECEDENT HAD RECENTLY BEEN ARRESTED ON DRUG CHARGED AND HAD BEEN IN DRUG REHAB.

JERRY McKIBBEN 478328 INVESTIGATOR DATE: **9/27/2012** TIME: **00:09** REVIEWED BY: *[Signature]* DATE: **9/27/12** TIME:

FORM #3 NARRATIVE TO FOLLOW?



County of Los Angeles, Department of Coroner Investigator's Narrative



Case Number: 2012-06359

Decedent: LEWIS, JONATHAN KENDRICK

Information Sources:

- Detectives Zesati & Martin – Los Angeles Police Department - Northeast, 3353 San Fernando Rd Los Angeles, CA 90065 (213) 485-2563

Investigation:

On 09/26/2012 at 1217 hours, Los Angeles Police Detective Carrillo reported this death to the Coroner's Office. Lieutenant Corral assigned this case to me at 1430 hours. I arrived at the location at 1453 hours. I cleared the scene at 1745 hours, after completion of the field portion of the investigation. I utilized the above sources and my on scene investigation to obtain the information contained within this death investigation report. The decedent is the suspect in a Homicide (Coroner Case # 2012-06358) that occurred at the same location just prior to his death.

Location:

Driveway – 3605 Lowry Road, Los Angeles, CA 90027

Informant/Witness Statements:

According to Detective Martin, the decedent is a 28-year-old white male who had rented a room at the above house two days ago. On 09/26/2012 at approximately 1030 hours, Los Angeles Police Dispatchers started receiving 911 calls regarding a women screaming from residents in the area. At about the same time the decedent jumped over the fence to the neighboring residence and became involved in a physical altercation with a painter working at that location and two adult residents. The decedent then jumped back over the fence to the above location and returned to the residence. When Los Angeles Police Officers arrived at the location they found the decedent lying supine near the top of the inclined driveway. He was noted to have head trauma. Los Angeles Fire Department Engine 56 arrived at the location and examined the decedent. He was found to have no signs of life and death was pronounced on 09/26/2012 at 1057 hours. As police continued to search the residence they discovered a female decedent in the residence. (Coroner Case 2012-06358). The decedent (Lewis) is believed to be the suspect in the homicide death of this female who is believed to be the homeowner and his landlord. The residence is located on a terraced hillside with the driveway below the level of the house. It appears that the decedent jumped over a wrought iron railing at the top of the terrace to drop to the driveway below during his attempt to flee the location. During this jump the decedent lost his balance and landed on the concrete driveway head first. A blood splatter is noted on the driveway below the railing. The decedent's momentum caused him to slide across the driveway where he came to rest along the outside edge of the driveway.

According to Mr. Lewis, the decedent has a recent history of drug abuse. He had been released from Los Angeles County Jail on 09/21/2012 for a drug related arrest. He had also recently undergone treatment at a drug rehab facility. Mr. Lewis confirmed that the decedent had just rented a room at the above location.

Scene Description:

The scene is a two story single family home that is located on a winding hillside road in the Los Feliz area of Los Angeles. The residence is on a terraced hillside above the roadway. A curving inclined driveway leads up from the street to the garage. A set of retaining walls separates the driveway from another terrace above where the home is located. A patio around the house is lined with a wrought iron railing. A set of steps leads from the driveway to this upper terrace. The elevation difference between the top of the driveway to the top of the railing is approximately 15 feet. Much of the retaining wall is covered in ivy. A short section of retaining wall separates the



County of Los Angeles, Department of Coroner
Investigator's Narrative



Case Number: 2012-06359

Decedent: LEWIS, JONATHAN KENDRICK

driveway from the stairway. The steps are on the west side of the driveway. The decedent is observed lying in supine position on the east side of the driveway. A blood splatter is noted on the west side of the driveway near the base of the stairs, below the elevated terrace and railing. A skid mark from the decedent's pants is noted going across the driveway from the area of the blood splatter to where the decedent came to rest. He has some blood stains on his arms, torso and clothing that do not appear to be from his wounds.

Evidence:

While at the scene, I collected a Decedent Fingernail Kit. This kit and the decedent's pants and shoes were released at the scene to the Los Angeles Police Department. The Los Angeles Police Department was also granted permission to collect seven swabs for evidence from the decedent's arms, neck and torso. These were collected by Los Angeles Police Department Criminalist B. Streiffert # N4624 at the scene prior to removal of the decedent.

Body Examination:

The body is that of a 28-year-old male who was observed lying on the driveway at the above location. He has blue eyes and brown hair. He is wearing blue jeans and red shoes. He has no scars noted. He has tattoos of stars on both shoulders. He has a tattoo of a symbol on his upper back. He has a laceration on the left side of his head. He has multiple abrasions and contusions and minor lacerations on his neck and arms. He has a wound on his right chest. Lividity is consistent with the position found. This lividity blanches with pressure. Rigor mortis is rated at three throughout the entire body. At the time of his removal there was some skin slippage noted to his chest and torso.

Identification:

On 09/26/2012 at 1842 hours, Los Angeles County Regional Identification System identified the decedent as Jonathan Lewis (DOB 10/19/1983) by fingerprint comparison.

Next of Kin Notification:

On 09/26/2012 at 1845 hours, family members notified _____ of the death of his son.

Tissue Donation:

The decedent is not a candidate for tissue donation due to probable drug abuse and recent incarceration.

Autopsy Notification:

No notification is needed for the examination in this case.


JERRY McKIBBEN
#478328


SUPERVISOR

09/26/2012

Date of Report

6

WAS ORIGINAL SCENE DISTURBED BY OTHERS? Y [] N [X]

IF YES, NOTE CHANGES IN NARRATIVE FORM #3.

DATE 9/26/2012

AMBIENT #1 _____ °F TIME _____

AMBIENT #2 _____ °F TIME _____

WATER _____ °F TIME _____

2012-06359
Lewis, Louisa
Acc / Suic
LAPD - NE
THERMOMETER # _____

LIVER TEMPERATURE #1 _____ °F TIME _____

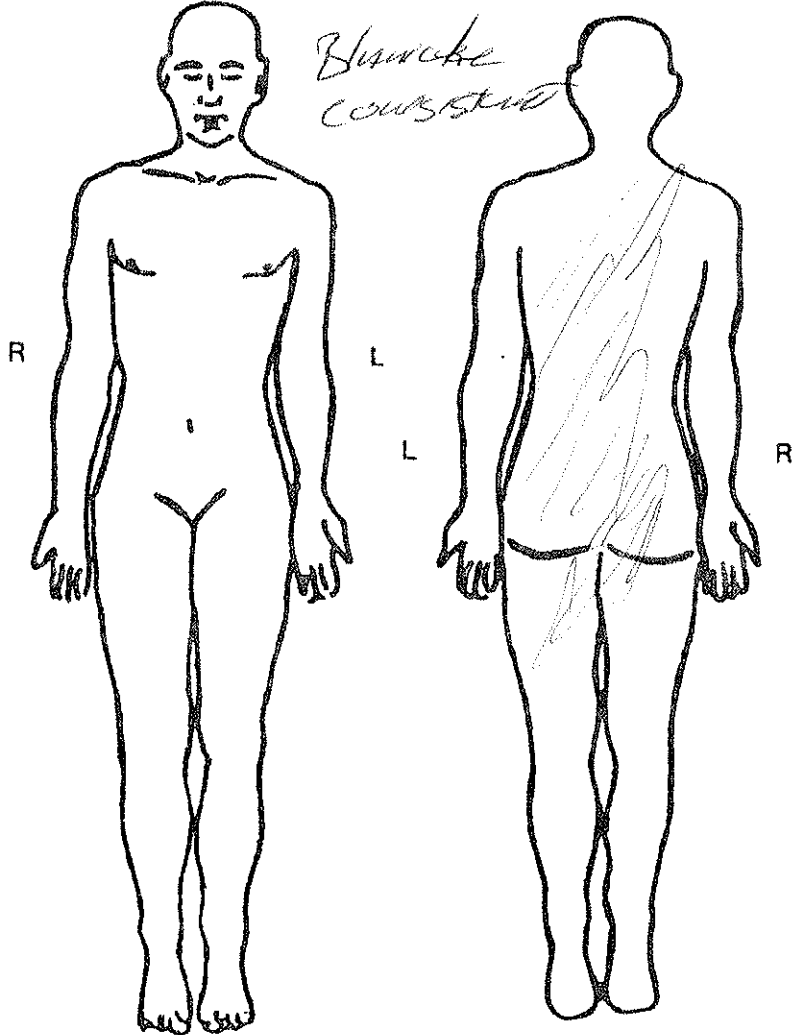
LIVER TEMPERATURE #2 _____ °F TIME _____

DATE & TIME FOUND 9/26/12 @ 1057 LAST KNOWN ALIVE 9/20/12 1040

APPROX. AGE 28 SEX M EST. HEIGHT 67 EST. WEIGHT 148 CLOTHED? YES [X] NO [] IF YES, DESCRIBE:
Blue pants, Red shoes

DESCRIPTION AS TO WHERE REMAINS FOUND AND CONTACT MATERIAL TO BODY:
Lying supine on driveway

SCENE TEMPERATURE REGULATED? YES [] NO [] IF YES, THERMOSTAT SET AT _____ DEGREES F.
LIVOR MORTIS: TIME OBSERVED 1710 RIGOR MORTIS: TIME OBSERVED 1710



- NECK FLEXION:
- ANTERIOR 3
 - POSTERIOR 3
 - RT. LATERAL 3
 - LT LATERAL 3
- JAW 3 HIP 3
- SHOULDER 3 KNEE 3
- ELBOW 3 ANKLE 3
- WRIST 3

SCALE

- 0 = ABSENT/NEGATIVE
- 1 -
- 2 -
- 3 +
- 4 = EXTREME DEGREE

USE SCALE TO DESCRIBE INTENSITY OF RIGOR MORTIS.

SHADE DIAGRAMS TO ILLUSTRATE THE LOCATION OF LIVOR MORTIS.

DESCRIBE INTENSITY OF COLORATION AND WHETHER LIVOR MORTIS IS PERMANENT OR BLANCHES UNDER PRESSURE.

CORONER'S INVESTIGATOR [Signature]

REVIEWED BY: [Signature]


12

AUTOPSY REPORT

No.

2012-06359

LEWIS, JONATHAN K.

I performed an autopsy on the body of  at _____ the DEPARTMENT OF CORONER

Los Angeles, California on SEPTEMBER 27, 2012 @ 0900 HOURS
(Date) (Time)

From the anatomic findings and pertinent history I ascribe the death to:

(A) TRAUMATIC INJURIES

DUE TO, OR AS A CONSEQUENCE OF

(B)

DUE TO, OR AS A CONSEQUENCE OF

(C)

DUE TO, OR AS A CONSEQUENCE OF

(D)

OTHER CONDITIONS CONTRIBUTING BUT NOT RELATED TO THE IMMEDIATE CAUSE OF DEATH:

Anatomical Summary:

28-year-old white male.

Partial strangulation.

Nail marks on both sides of the neck.

Hemorrhage of the right sternomastoid, right sternohyoid, right sternothyroid and left sternohyoid muscles.

Hemorrhagic fracture of the right superior horn of the thyroid cartilage.

Calvarial and basal skull fracture, left frontal.

Subdural and subarachnoid hemorrhage, diffuse, brain.

Contusion hemorrhage, right and left orbital gyri and left inferior temporal lobe.

Bloody cerebrospinal fluid.

Contusions of the mid-back.

Vertebral column fractures.

Nondisplaced fracture of C-3.

Displaced fracture of T-8.

Compression fracture of L-1.

12**AUTOPSY REPORT**

No.

2012-06359

LEWIS, JONATHAN K.

Page 2

Multiple displaced rib fractures, posterior right costovertebral angle, ribs 3-10, left costovertebral angle, ribs 3-7.

Traumatic hemomediastinum with laceration of the inferior vena cava.

Traumatic hemothorax, right, 100 cc.

Multiple skin abrasions and contusions of the torso and upper extremities.

Wrist scars, bilateral.

Please see separate toxicology report.

EXTERNAL DESCRIPTION:

The body is that of a slim, red-haired white male with rigor mortis passing off. Identifying marks consist of a small triangular tattoo at the posterior base of the neck and a 5-pointed star tattooed on either lateral deltoid area. Also there are small well healed scars on the anterior aspect of the both wrists. On the left there is a 1 inch longitudinal scar and on the right wrist laterally over the radius there are several approximately 5/8 inch longitudinal scars. Examining the back we find several large, slightly swollen purple contusions over the thoracic vertebral column beginning about the T-5 level and going down as far as L-1.

HEAD:

The head has a palpable displaced and depressed fracture. The frontal bone just to the left of the midline with a large swollen ecchymosis of the left orbit and left lateral forehead overlying the fracture, evidencing a hematoma. The ear canals are empty. There are no petechiae of the eyes or face.

12**AUTOPSY REPORT**

No.

2012-06359

LEWIS, JONATHAN K.

Page 3

NECK:

On the right lateral neck are numerous small linear abrasions which are brown in color measuring from $\frac{1}{4}$ inch up to $\frac{5}{8}$ of an inch approximately in size, and mostly horizontal in orientation. On the left neck there are two red, thin linear abrasions each more than an inch long running horizontally.

CHEST:

On the chest just medial to the right portion of the right breast there is an irregular brown skin abrasion which has an arc-like component and an irregular patch-like component. I do not see any definite teeth marks and the form is not typical for a bite mark.

RIGHT UPPER EXTREMITY:

On the back of the right elbow above the joint there is a 2 inch red contusion.

LEFT UPPER EXTREMITY:

There is an approximately $\frac{1}{2}$ inch horizontal brown abrasion in the lateral part of the left cubital fossa, two small abrasions on the lateral distal left radius, and an abrasion on the medial part of the thenar eminence of the left palm surrounded by a 2 inch red swollen contusion, and the left hand. On the back of the left upper extremity there are two deep brown abrasions near the elbow and two along linear abrasions on the posterior surface of the left forearm as well as one on the left wrist.

RIGHT UPPER EXTREMITY:

On the back of the right upper extremity there is a contusion above the elbow. On the back of the right hand shows contusions on the posterior aspects of the 2nd, 3rd, and 5th finger.

12**AUTOPSY REPORT**

No.

2012-06359

LEWIS, JONATHAN K.

Page 4

PRIMARY INCISION:

A Y-shaped incision was used to enter the body cavities. We find a 100 cc liquid unclotted right-sided traumatic hemothorax. The left pleural cavity contains only about 25 cc of clear serosanguinous fluid. There are no injuries in the abdomen and no blood or fluid collections. No intrathoracic petechiae and no anterior rib fractures.

CARDIOVASCULAR SYSTEM:

The heart weighing 300 grams, is empty of blood. Epicardium is normal. Pericardial space contains 25 cc of clear colorless, watery fluid. The coronary arteries are thin walled, pliable and widely patent throughout. Heart muscle and valves are normal. No abnormalities of the myocardium or endocardium. The aorta is intact all the way down but is surrounded by a prominent hemomedistinum from the T-3 level down to the T-12 level.

GASTROINTESTINAL SYSTEM:

The mid esophagus surrounded by a large mediastinal hematoma. The stomach is empty. The intestinal tract is unremarkable. Appendix is present. Normal bowel contents.

HEPATOBIILIARY SYSTEM:

The liver weighing 1150 grams, is soft and brown and smooth. The gall bladder is present. It contains bile which is collected for toxicology. Pancreas normal.

URINARY SYSTEM:

The right kidney weighs 140 grams. The left kidney weighs 130 grams. The kidneys are smooth and unremarkable. The ureters are normal. Urinary bladder is dilated and contains 200 cc of clear yellow urine, which a sample is collected in gray top tube for toxicology.

12**AUTOPSY REPORT**

No.

2012-06359

LEWIS, JONATHAN K.

Page 5

GENITAL SYSTEM:

Normal uncircumcised male. Both testes are descended and are without injury. There is postmortem drying artifact of the skin of the scrotum which is otherwise unremarkable. Prostate gland is normal.

HEMOLYMPHATIC SYSTEM:

The spleen weighing 150 grams, is intact and unremarkable. Lymph nodes are small.

ENDOCRINE SYSTEM:

Pituitary, thyroid and adrenal glands are unremarkable.

CENTRAL NERVOUS SYSTEM:

Reflection of the scalp discloses a prominent and very large subgaleal hematoma on the left frontal and temporal areas overlying a displaced sagittal fracture of the left frontal bone extending from the vertex all the way down into the orbital area, and from there posteriorly into the left middle cranial fossa, as diagramed on Form #28. Opening skull reveals diffuse thin film, subdural hemorrhage covering both cerebral hemispheres, also diffuse subarachnoid hemorrhage covering both cerebral hemispheres. The cerebral spinal fluid is grossly fluid. Examining the brain which weighs 1440 grams, and is non-swollen, we find prominent fresh contusion hemorrhage covering the left orbital gyri and focally on the right orbital gyri, and also on the inferior surface of the left temporal lobe (fracture contusion). The brain is otherwise unremarkable. Removal of the dural mater discloses the above described fractures.

MUSCULOSKELETAL SYSTEM:

In addition to the above described skull fracture, we find a nondisplaced hemorrhagic anterior body fracture of the 3rd

12**AUTOPSY REPORT**

No.

2012-06359

LEWIS, JONATHAN K.

Page 6

cervical vertebra, a displaced hemorrhagic fracture of the 8th thoracic vertebra, and a nondisplaced hemorrhagic compression fracture of the body of the 1st lumbar vertebra. In addition to the above mentioned hemomediastinum there is prominent subpleural hemorrhage on the right with the associated large right-sided traumatic hemothorax and removal of parietal pleura discloses markedly displaced rib fractures at costovertebral angles of right ribs 3-10 and left ribs 3-7 with surrounding hemorrhage.

PHOTOGRAPHY:

I had photographs taken prior to autopsy.

TOXICOLOGY:

I collected chest blood for toxicology and also in the purple top tube. I collected femur blood by iliac needle. Also representative samples of urine, bile, liver and vitreous humor and a comprehensive screen is asked for. Please see separate toxicology report.

WITNESSES:

Detective Martin is present and witnesses the autopsy.

OPINION:

Decedent died of a fall. We do not have definitive evidence that the decedent intended to kill himself. We also do not at this time have any evidence that he was pushed. Therefore, the manner of death is accidental.



JAMES K. RIBE, M.D.
SENIOR DEPUTY MEDICAL EXAMINER

10. 29. 12
DATE

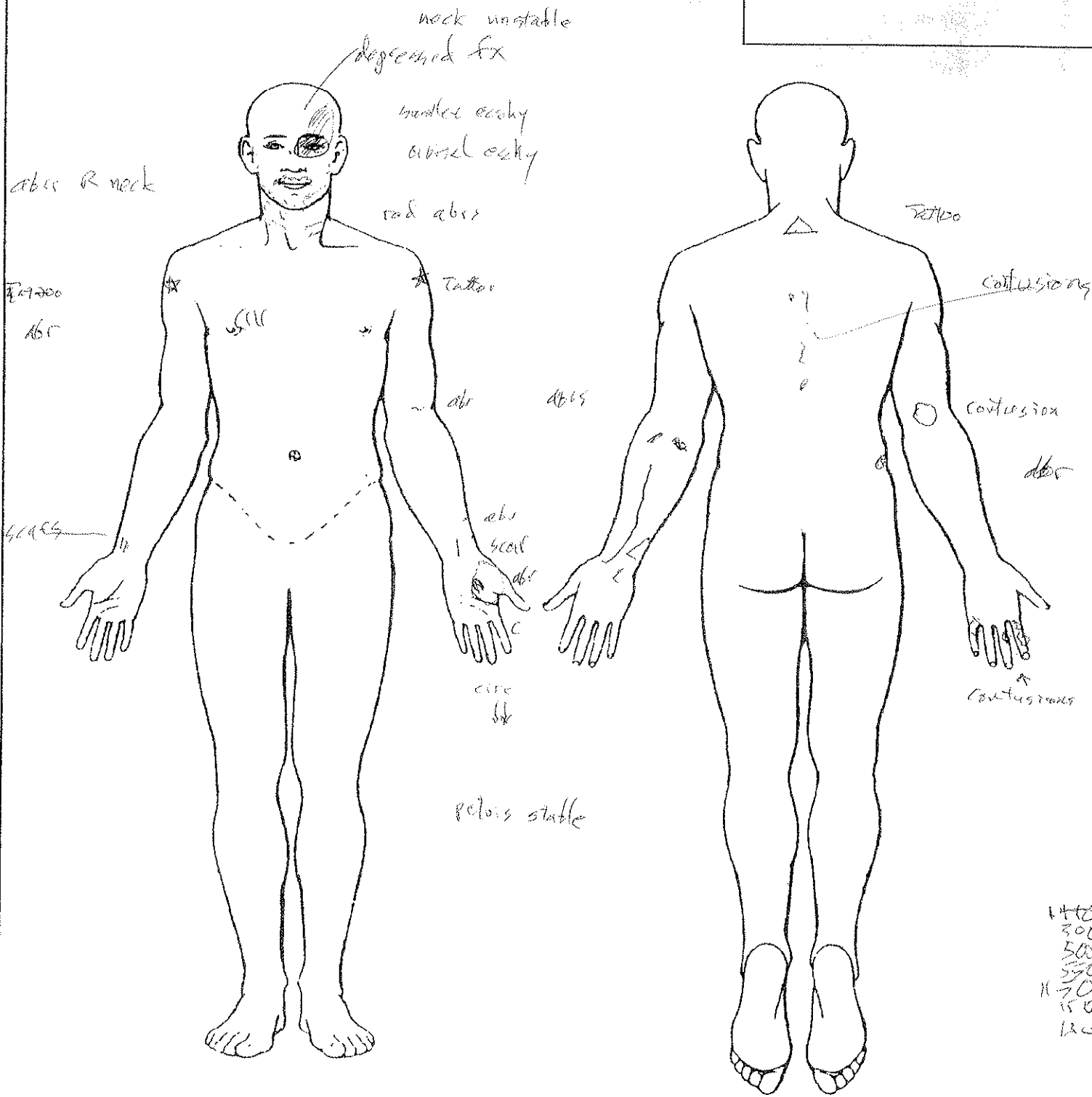
JKR:bbtt/mp
D-09/27/12
T-10/03/12

20

slim white male
rigor passing off

2012-06359
LEWIS JONATHAN
M/S

62



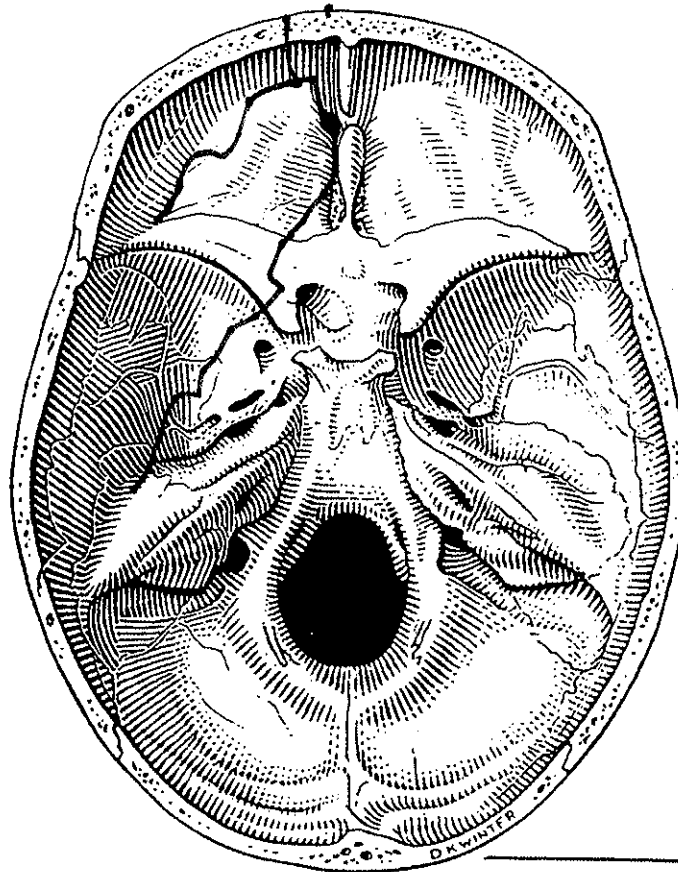
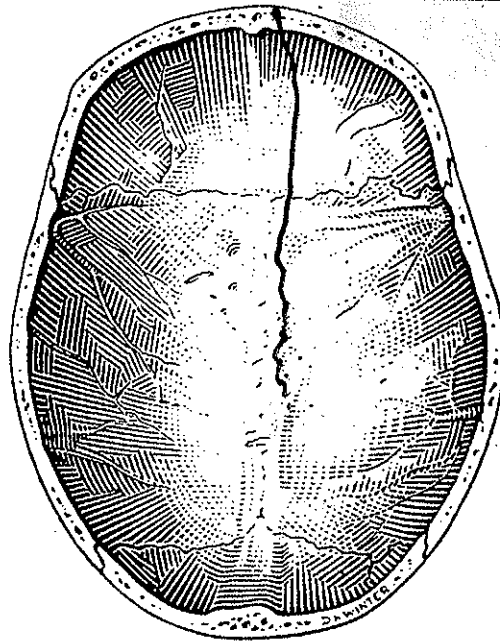
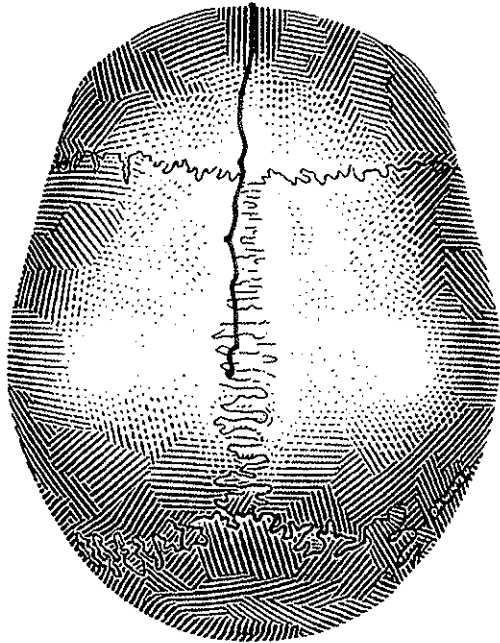
Date 9 . 27 . 12

[Signature] M.D.
Deputy Medical Examiner

28

2012-06359
LEWIS JONATHAN
8/8

b2



fx

D. WINTER

9/27

M.D.

Deputy Medical Examiner

16

2012-06359
LEWIS JONATHAN
A/S

52

EXTERNAL EXAM

Sex *M*
Race *C*
Age *28*
Height
Weight
Hair
Eyes
Sclera
Teeth
Mouth
Tongue
Nose
Chest
Breasts
Abdomen
Scar
Genital
Edema
Skin
Decub
HEART Wt. *300*
Pericard
Hypert
Dilat
Muscle
Valves
Coronar

RV
LV
Septum

AORTA

VESSELS

LUNGS Wt
R *500*
L *750*

Adhes
Fluid *170*
Atelectasis
Oedema
Congest
Consol
Bronchi
Nodes

PHARYNX

TRACHEA

THYROID

THYMUS

LARYNX *fx (R)*

HYOID

ABDOMINAL WALL FAT *1/2"*

PERITONEUM

Fluid
Adhes
LIVER Wt *1150*
Caps
Lobul *smooth*
Fibros
G B *present*
Calc
Bile ducts

SPLEEN Wt *170*

Color
Consist
Caps *intact*
Malpig

PANCREAS

ADRENALS

KIDNEYS Wt

R *130*
L *130*
Caps
Cortex
Vessels
Pelvis
Ureter

BLADDER *200 cc*

GENITALIA

Prost
Testes
Uterus
Tubes
Ovar

OESOPHAGUS

STOMACH

Contents *0*

DUOD & SM INT

APPENDIX *present*

LARGE INT

ABDOM NODES

SKELETON

Spine *fix*
Marrow
Rib Cage *fix*
Long bones
Pelvis

SCALP

CALVARIUM

BRAIN Wt *1440*

Dura
Fluid *bloody*
Ventric
Vessels
Middle ears
Other

PITUITARY

SPINAL CORD

TOXICOLOGY SPECIMENS

*chest blood, femoral blood, EDTA
liver bile urine vit*

SECTIONS FOR HISTOPATHOLOGY

1 can

MICROBIOLOGY

DIAGRAMS *20, 28*
X-RAYS

OTHER PROCEDURES

ID photo

GROSS IMPRESSIONS

on form 42

Date

9-27-12

Time

9:00

Deputy Medical Examiner

[Signature]



Department of Coroner, County of Los Angeles
FORENSIC SCIENCE LABORATORIES

1104 North Mission Road Los Angeles, CA 90033



Laboratory Analysis Summary Report

Ribe, James M.D.

Deputy Medical Examiner
 1104 North Mission Road
 Los Angeles, CA 90033

Pending Tox

The following results have been technically and administratively reviewed and are the opinions and conclusions of the Analyst:

Coroner Case Number: 2012-06359 **Decedent:** LEWIS, JONATHAN KENDRICK

<u>SPECIMEN</u>	<u>SERVICE</u>	<u>DRUG</u>	<u>RESULT</u>	<u>ANALYST</u>
Blood, Chest				
	Alcohol-GC/FID-HS	Ethanol	Negative	M. Schuchardt
	Bases-GC/NPD &/or MS	Basic Drugs	ND	S. DeQuintana
	ELISA-Immunoassay	Barbiturates	ND	B. Ciullo
	ELISA-Immunoassay	Cocaine and Metabolites	ND	B. Ciullo
	ELISA-Immunoassay	Fentanyl	ND	B. Ciullo
	ELISA-Immunoassay	Marijuana: Carboxy-THC	ND	B. Ciullo
	ELISA-Immunoassay	Methamphetamine & MDMA	ND	B. Ciullo
	ELISA-Immunoassay	Opiates: Codeine & Morphine	ND	B. Ciullo
	ELISA-Immunoassay	Opiates: Hydrocodone & Hydromorphone	ND	B. Ciullo
	ELISA-Immunoassay	Phencyclidine	ND	B. Ciullo
	GC/MS	Sympathomimetic Amines	* ND	C. DalChele
	LC/MS	Anti-psychotic Drugs (Atypical)	ND	J. Lintemoot
	Neutrals-GC/MS	Neutral Drugs	ND	O. Pleitez
Urine				
	GC/MS	Sympathomimetic Amines	* ND	C. DalChele

NOTE: *Includes compounds such as 2-Cl, Methedrone, Mephedrone, Methylone, and Methcathinone.

Legend:

mg/dL	Milligram per Deciliter	QNS	Quantity Not Sufficient
g	Grams	TNP	Test Not Performed
g%	Gram Percent	ug	Micrograms
Inc.	Inconclusive	ug/g	Micrograms per Gram
mg	Milligrams	ug/mL	Microgram per Milliliter

In accordance with the Department's Evidence Retention Policy, the blood specimen(s) will be retained for one-year and all other specimens for six-months from Autopsy.

Administratively reviewed by:

Daniel T. Anderson, M.S., FTS-ABFT, D-ABC
Supervising Criminalist II
TOXICOLOGY

(323) 343-0660 Danderson@coroner.lacounty.gov

JCR
 11-23-12